

HAND SURGERY

Q U A R T E R L Y



ANNUAL MEETING 2004 PREVIEW

Courses, Cases and Camaraderie

The 34th Annual Meeting of the American Association for Hand Surgery (AAHS) will be held at the beautiful Westin Mission Hills in Palm Springs, California, from January 14-17, 2004. Over 70



**WARREN SCHUBERT,
MD**

papers have been accepted covering all areas of hand surgery. The program is designed so that participants will have time off in the afternoons to spend with their families and colleagues.

Various social events are scheduled each evening. In addition to multiple papers, there will be 20 instructional courses over the four days of the meeting. For the first time we will also be offering 12 computerized instructional courses. A wide range of topics will be covered, including the management of the mangled hand, wrist fractures and arthritis, Dupuytren's, peripheral nerve injury, brachial plexus surgery, the congenital hand, and more. There will be several concurrent panels with world authorities discussing the controversies of the management of radial nerve palsy, thumb carpometacarpal joint disease, nerve

decompression, and nerve reconstruction in the upper extremity. Our Association president, Dr. Allen Van Beek, will chair a session presenting challenging and controversial cases to the past presidents of the AAHS, asking them how they would manage

decompression, and nerve reconstruction in the upper extremity.

Our Association president, Dr. Allen Van Beek, will chair a session presenting challenging and controversial cases to the past presidents of the AAHS, asking them how they would manage



these difficult cases.

January 14, our first day of the meeting, will include a focus on hand therapy, including joint dissociation, fracture management, and nerve injuries. This will be followed by five concurrent courses in the afternoon, and our reception in the evening. Our last day, January 17, will continue our tradition of participating in a combined day with the American Society for Reconstructive Microsurgery (ASRM) and the American Society for Peripheral Nerve (ASPN). Special courses and papers that would be of interest to all three groups will be presented on this day.

The Presidents Invited Lecturer will be Dr. John McDonald, who will present his work on spinal cord regeneration. Keynote



speakers will include Drs. Susan Mackinnon and Elvin Zook.

In addition to special programs and activities offered each evening, there are several special programs during the day. The venue includes great golfing, golf tips from the pros, a program on art in orthopedics and a special program on learning home video and DVD for family. For those who will be attending this meeting for the first time, this meeting has a reputation of encouraging participants to bring their families.

We would like you to consider staying in Palm Springs after our hand meeting and attending the ASPN and ASRM meetings as well.

Be prepared for a meeting with fun in the sun, science, camaraderie and activities for your whole family. I look forward to seeing you in Palm Springs!

*Warren Schubert, MD
2004 Scientific Program Chair*

A Fish Story

I have just finished reading an interesting book: *Cod*, by Mark Kurlansky (Penguin, New York, 1997). The book is, simply, the contemporary history of a fish, the North Atlantic cod, and its effect on Western history. It makes fascinating reading, and, as you will see, has some lessons for us as well.

The book starts in the Middle Ages, when fish was cheap protein for the European masses, and Basque fishermen provided tons of cod, from a secret fishing ground far to the west. Later, explorers discovered that the Basques' secret fishing spot was the Grand Banks, a vast shallows off the Newfoundland coast, where John Cabot in 1497 described

being able to simply lower baskets into the water, and heave them up, brimming with fat cod.

The supply seemed inexhaustible. For nearly five centuries, European and later North American fishermen first fished, then trawled the waters of the Grand Banks. Cod fishing rights were so important to the United States and Great Britain their resolution delayed, by two years, the signing of the treaty that ended the Revolutionary War. To this day, a life sized replica of a cod hangs in the Massachusetts State House, a testimony to the importance of the cod fishery to that state's economy over the years. The entire Newfoundland economy was based on cod, and the value of the catch was one reason why a fish-and-chips-addicted Britain kept Newfoundland as a colony until the middle of the twentieth century, long after it had given self rule to the rest of what is now Canada (which also explains why that island has its own time zone, thirty minutes out of kilter with its neighbors).



PETER C. AMADIO, MD

There were warning signs of trouble on the Grand Banks early in the last century, when new trawling methods led to massive catches, and a depletion of the biggest cod, but then the fish had returned. Temporary halts to the massive fishing, a result of recruiting the trawlers and their crews for two World Wars, gave the cod population a last chance to recover. Finally, and rather precipitously, the catch plummeted to nearly nothing in the 1980's. Marine scientists brought in to study the matter at first thought that time would rectify the situation, as it had before. But this time, it appeared that the breeding stock had been irreparably damaged, and the duration of the depletion of the cod schools had allowed other marine species to occupy the cod's ecological niche on the Grand Banks. It seems unlikely now that the cod will ever return there in great numbers.

The impact of all this on the economies of New England and Canada has been substantial. Fish are still a big business around the world, of course, but Grand Banks cod is not. The British have had to turn to other sources, and other species, for their fish. Yet centuries of habit, and culture, are hard to change. Especially in Newfoundland, in many communities the most common occupation is 'unemployed cod fisherman'.

Kurlansky closes by discussing man's impact on ecology and the tragedy of the commons, in which regulation (in this case, of the annual catch) is in the long term interest of the group as a whole, but goes against the short term profit interest of every individual in the group. But to me there is another message, which relates not just to unemployed fishermen, but to all of us. The message is that there is a life cycle to every activity, which we ignore at our peril.

Which brings me back to you and me. Like the fishermen in *Cod*,

we like the status quo. But, eventually, the status quo can no longer be supported. When it has been in place for generations, as the cod was, it is an especially big disruption. I'm sure you can think of ways in which our cod catch is not like it was. Who hasn't wished for the good old days of fee for service at 100% reimbursement, no HMO's, no HIPAA, and no malpractice suits? Like the Newfoundland fishermen who keep going out in their dories at dawn, we even have our own dawn patrol, as our professional societies send out lobbyists by the score, even though, like the fishermen, they return home empty handed every night. Like the fishermen, too, we can be stubborn in our ways. Even in our practice habits, we don't like having to look for new fish. How good are we at adopting best medical practices? Not much better than the fishermen were at safeguarding their commons, according to most of the patient safety literature. Too often, doctors operate on the wrong site, administer the wrong drugs, or practice in ways not supported by evidence, all because we are reluctant to replace old ways of doing things with new ones. Old habits are hard to break, but we must try harder. Some things that are old, and comfortable, and familiar, like the Grand Banks cod fishery, and maybe your favorite way of treating condition X, or the way you like to organize your office, will disappear. New things will take their place. Eventually these new things will become old, and comfortable, too. Then they will change as well. It is the way of the world. Good new days will come, but the good old days will not return, even though, while they were here, it seemed like they would last forever. Like the cod. **H**

Best of the Best

The best hand surgeons in the world are meeting in Palm Springs, California, during the AAHS's Annual Meeting January 14-17. Pre-register now at handsurgery.org and, by the way, you don't have to buy recognition that you are the best. AAHS membership, participation in AAHS educational programs and your surgical skills have already made you one of the best of the best. In Palm Springs expect to continue to learn the latest techniques in hand surgery, the hot topics in hand surgery, and emerging technologies while having a relaxing time on the grounds of a wonderful resort.

HAND SURGERY QUARTERLY

President

Allen Van Beek, MD

Editor

Peter C. Amadio, MD

Executive Director

Laura Downes Leeper, CAE

Managing Editor

Anne B. Behrens

Hand Surgery Quarterly is a publication of The American Association for Hand Surgery and is published strictly for the members of AAHS. This publication is designed as a forum for open discussion and debate among the AAHS membership. Opinions discussed are those of the authors or speakers and are not necessarily the position, posture or stance of the Association.

Copyright ©2003, The American Association for Hand Surgery. All rights reserved. No portion of this newsletter may be printed without express written permission from the publisher, 20 N. Michigan Avenue, Suite 700, Chicago, IL 60602, 312-236-3307.

AAHS will continue the tradition of excellence in learning combined with fun. Keynote speakers Dr. Elvin Zook and Dr. Susan Mackinnon are career educators and will teach and challenge us with their discussions. The concept of individual learning using computer based "poster sessions" created by experts will let you choose where you want more emphasis in your practice.

The scientific session, panels, and instructional courses are structured to avoid repetition and bring new concepts and instructors to the forefront. Plan to stay after the Hand meeting and attend the American Society for Reconstructive Microsurgery meeting and the American Society of Peripheral Nerve meetings for focused discussion using microsurgery for Hand Reconstruction.

Bring your golf clubs, sun tan lotion, families, pets and credit cards. The golf course is challenging, shop where Hollywood celebrities shop, and enjoy the wide choice of family entertainment venues. An excellent resort day care center complete with youth activities makes it easy for moms to have a time out.

This will be my last AAHS newsletter report "From the President." The past ones have focused on information dissemination and accumulation—something I will continue to pursue after my replacement by one of the best of the best, Dr. Richard Berger.

A very exciting and recent summit is renewing interest in the AAHS by the American Society of Plastic Surgeons. The realization in a recent survey that many plastic surgeons have significant portions of their practices involving hand surgery and that even cosmetic surgeons have an interest in the hand caught the attention of James Wells, MD, Immediate Past President of the ASPS and an AAHS member.

He arranged a leadership summit that featured the leadership of AAHS, ASRM, ASPN, and ACPA. He is committed to continuing efforts to foster the efforts of reconstructive surgeons within the ASPS to include strategic planning, educational planning, maintenance of certification and public awareness. The presence of AAHS members participating on the ASPS and Plastic Surgery Educational Foundation's boards are powerful concepts. The AAHS needs to provide skilled leaders to fill those positions and help plastic surgeons throughout the world. I'm not aware of data regarding the percentage of hand surgery that most orthopedists have within their practice. AAHS does not have a board seat on the AAOS board but AAHS has had discussions with AAOS and ASSH regarding AAHS involvement with AAOS hand specialty day. This will allow an orthopedist interested in hand surgery to experience the teaching skills, knowledge and experience that members of the AAHS possess. It is apparent that organizations such as AAOS and ASPS will influence AAHS membership, as their members with little desire to obtain a CAQ but still actively performing hand surgery look for affordable educational and active membership benefits that meet their needs. As our membership numbers increase, so will the complexity of the organizational chart of AAHS, but the goals of educational excellence, research, and establishing lifetime friendships combined with fun, will always ensure that our members are the best of the best. AAHS's future is bright because of its members' commitment and its future leadership. **H**



ALLEN L. VAN BEEK, MD

AAHS 34th Annual Meeting

January 14–17, 2004
Westin Mission Hills
Palm Springs, California

Hand Therapy Specialty Day Wednesday, January 14, 2004

Hand Therapy Through the Ages

- 6:30–7:00 am** Coffee
- 7:00–7:05 am** **President's Welcome**
Allen Van Beek, MD
-
- 7:05–10:20 am** **Joint Dissociation and Fracture Management Through the Ages**
Moderator: Sue Michlovitz, PT, PhD, CHT
- 7:05–7:20 am Fracture Healing
Julianne Howell, MS, PT, CHT
- 7:20–7:50 am Distal Radius Fracture
Brian Adams, MD
Sue Michlovitz, PT, PhD, CHT
- 7:50–8:20 am Scaphoid Fracture
Mark Baratz, MD
Georgette Fogg, OTR/L
- 8:20–8:50 am Monteggia Fracture
Robert Goitz, MD
Gail Groth, PT, CHT
- 8:50–9:20 am Radial Head Fractures
Paul Brach, MS, PT, CHT
Dean Sotereanos, MD
- 9:20–9:50 am TFCC
Richard Berger, MD
Paul LaStayo, PT, PhD, CHT
- 9:50–10:20 am Elbow Dislocation
Robert Slater, MD
Aviva Wolff, BSc, OTR/L, CHT
- 10:20–10:30 am** **Break**
-
- 10:30 am–12:00 pm** **Nerve Injuries Through the Ages**
Moderator: Dean Sotereanos, MD
- 10:30–11:00 am Diagnosis and Outcome of Complex Nerve Injuries
Christine Novak, MS, PT
- 11:00–11:30 am Evaluation and Management of Brachial Plexus Birth Palsy
Susan Duff, Ed.D, PT, OTR/L, CHT
Scott Kozin, MD
- 11:30 am–12:00 pm Rehabilitation and Management of Complex Nerve Problems
Joan Collins, OTR/L, CHT
Allen Van Beek, MD

12:00–1:00 pm Lunch

- 1:00–3:00 pm** **The Performing Artist: Then vs Now**
Moderator: Keith Bengston, MD
- 1:00–1:45 pm History of the Harmonica in Blues Music: An Interactive Presentation
Mark Baratz, MD
- 1:45–2:15 pm Medical Management of the Performing Artist: Then vs Now
Peter Amadio, MD
- 2:15–2:45 pm Therapeutic Management of the Performing Artist: Then vs Now
Peter Amadio, MD
Lauren Valdata-Eddington, PT, CHT
- 2:45–3:00 pm Discussion
- 3:00–3:15 pm** **2003 Vargas Award Winner**
- 3:20–4:35 pm** **Concurrent Instructional Courses**
- 101 Reconstruction of the Burned Hand
Bruce Brewer, MD
Roger Simpson, MD
- 102 The Mangled Hand and Replantation
W. P. Andrew Lee, MD
Bradon Wilhelmi, MD
David Ruebeck, MD
- 103 Extensor Tendon Repair and Rehabilitation
Joe Banis, MD
Scott Kozin, MD
Wyndell Merritt, MD
Miguel Saldana, MD
- 104 An Overview of Wrist Biomechanics
Brian Adams, MD
Richard Berger, MD

3:20–5:20 pm Concurrent Instructional Courses

- 105 Distal Radius Fractures
Alan Freeland, MD
William Geissler, MD
Amy Ladd, MD
Robert Medoff, MD
Jorge Orbay, MD
Matthew Putnam, MD
Scott Wolfe, MD

6:30–7:30 pm AAHS Welcome Reception

Enjoy sparkling conversations and beverages while sharing stories and experiences at the AAHS reception. Visit with old friends and meet new ones while tasting delicious hors d'oeuvres and enjoying a cocktail. A good time awaits one and all!

Cost: \$95 per person for an additional ticket

Thursday, January 15, 2004

6:00–7:00 am Coffee

6:30–7:40 am Instructional Courses

- 106 Phalangeal Fractures
Mark Baratz, MD -
Extraarticular Phalangeal Fractures
Alan Freeland, MD -
Intraarticular Phalangeal Fractures
Maureen Hardy, PT, MS, CHT -
Rehabilitation of Phalangeal Fracture
- 107 Management of the Arthritic Wrist
Craig Johnson, MD
Gunter Germann, MD
A. Lee Osterman, MD
- 108 Creating Multimedia Presentations
William Dzwierzynski, MD
George Landis, MD
- 109 Treatment of Pediatric Traumatic Hand Injuries (includes fractures)
Robert Russell, MD
Bradon Wilhelmi, MD
- 110 Rheumatoid Hand and Wrist
Brian Adams, MD
Matthew Tomaino, MD

7:00–5:00 pm Poster Session Open

8:00 am–4:00 pm Computerized Instructional Courses

Individualized learning stations focusing on latest techniques from a number of well-known physicians. You are welcome to visit Celebrity A anytime during open hours.

Total Wrist Arthroplasty
Brian Adams, MD

Reimbursement Issues in Micro Surgery
Keith Brandt, MD

First Carpal/Metacarpal DJD
Richard E. Brown, MD

Denervation as a Treatment Modality for Painful Joints
A. Lee Dellon, MD

Redo Ulnar Nerve
William Dzwierzynski, MD

Management of Carpal Bone Disassociation
Scott Kozin, MD

Arthroscopy
A. Lee Osterman, MD

Arthrodesis of the MCP Joint of the Thumb using a Low-Profile Plate
Miguel Pirela-Cruz, MD

Nerve Compression Syndromes
Allen Van Beek, MD

Replantation
Allen Van Beek, MD

TBA
Mark Baratz, MD

7:45–8:45 am Concurrent Panels

Management of Radial Nerve Palsy
Scott Kozin, MD
Susan Mackinnon, MD
Steve McCabe, MD

Thumb Carpometacarpal Joint Disease
Richard Berger, MD
Richard Brown, MD
A. Lee Osterman, MD

8:45–10:21 am Concurrent Scientific Paper Session

10:21–10:50 am Break

10:50–10:55 am AAHS Endowment
Miguel Saldana, MD

10:55 am–12:00 pm The J. Joseph Danyo Presidential Invited Lecturer I
Susan Mackinnon, MD
"Merging Science and Multidisciplinary Expertise: Nerve Allograft to Nerve Transfer"

12:00–12:20 pm Break

12:20–1:20 pm Concurrent Panels

Computers in Your Practice: Photography, PDA's, Archiving, & Presentations
Keith Brandt, MD
George Landis, MD
Daniel Nagle, MD

Failed Nerve Repair
Peter Amadio, MD
Christine Novak, PT, MS
Robert Russell, MD
Dean Sotereanos, MD

5:30–6:30 pm Family Programs:

Home Video and DVD for Family

Planning for Your Financial Future

Art and Orthopedics

Friday, January 16, 2004

6:00–6:30 am Coffee

6:30–7:45 am Instructional Courses

111 Dupuytren's Contracture
Vincent Rod Hentz, MD
Michael Jabaley, MD
Nicholas Vedder, MD

112 Malignant Bone and Soft Tissue Tumors of the Upper Extremity
Peter Murray, MD
Stephen Trigg, MD

113 Peripheral Nerve Repairs
L. Scott Levin, MD
Miguel Pirela-Cruz, MD
Dean Sotereanos, MD

114 Scaphoid Fractures
Kevin Chung, MD
William Pederson, MD
Munir Shah, MD

115 Congenital Hand
Amit Gupta, MD
Joseph Upton, MD

7:00 am–5:00 pm Poster Session

8:00 am–4:00 pm Computerized Instructional Courses (Continuation)

7:45–8:45 am Concurrent Panels

Nerve Decompression
Allen Bishop, MD
L. Scott Levin, MD
Nash Naam, MD
Walter Palermo, MD
Dean Sotereanos, MD
Robert Spinner, MD
Tsu-Min Tsai, MD

Clinical Challenges for the Past Presidents
Peter Amadio, MD
Robert Buchanan, MD
Alan Freeland, MD
Wyndell Merritt, MD
Robert Russell, MD
William Swartz, MD
Allen Van Beek, MD

8:45–10:21 am Concurrent Scientific Paper Session

10:21–10:50 am Break

10:50–10:55 am AAHS Endowment
Miguel Saldana, MD

10:55 am–12:00 pm The J. Joseph Danyo Presidential Invited Lecturer II
Elvin Zook, MD
"Gen-X. Out of Hand?"

12:00–12:20 pm ASSH & ISSH Presidential Remarks

12:20–1:20 pm President's Luncheon/AAHS Annual Business Meeting/Presidential Address

1:30–2:15 pm AAHS Board of Directors Meeting

**AAHS/ASRM/ASP
Combined Day Program**

Saturday, January 17, 2004

6:00–6:30 am Coffee

6:30–7:30 am Instructional Courses

Nerve Conduits
David Chiu, MD
A. Lee Dellon, MD
Yasushi Nakao, MD

Obstetrical Brachial Plexus Palsy
Howard Clarke, MD
Peter Waters, MD

Soft Tissue Coverage of the Hand (Micro and Non-micro)
Gunter Germann, MD
L. Scott Levin, MD
William Lineaweaver, MD
Julian Pribaz, MD

Preoperative and Intraoperative Nerve Assessment
Steve McCabe, MD
Walter Palermo, MD

Major Limb Replantation
Chris Pederson, MD
William Zamboni, MD

7:30–7:40 am Presidents' Welcome
Allen Van Beek, MD, AAHS
Ronald Zuker, MD, ASRM
Keith Brandt, MD, ASPN

7:40–8:55 am Panel: New Approaches to Nerve Reconstruction in the Upper Extremity
Warren Breidenbach, MD
A. Lee Osterman, MD
Christopher Oberlin, MD
John Taras, MD

8:55–9:40 am Presidents Invited Lecture
John W. McDonald, III, MD, PhD

9:40–10:15 am Coffee/Exhibits Break

10:15–11:15 am Outstanding Nerve Paper Presentations

11:30 am 8th Annual Day at the Links

Hand Surgery Quarterly

.....

Winter 2004

A Tribute to Joseph L. Posch, MD

The Joseph L. Posch, MD Award for the Best Resident/Fellows Presentation at the American Association for Hand Surgery Annual Meeting

Joseph L. Posch, MD, was a surgeon in Detroit, Michigan. He was particularly renowned for his expertise in hand surgery. He touched the lives of many patients and, of equal importance, he was one of the first to initiate postgraduate training of future generations of hand surgeons. Plastic, orthopedic, and general surgeons throughout the United States came to Grace Hospital in Detroit to learn from the master. Thirty hand surgeons that had trained with Dr. Posch since 1956 formed the Joseph L. Posch Hand Society as a tribute to their mentor. In 1967, they began their meetings to renew their friendship and to further their education by discussing the problems that they had encountered and the solutions that they had devised. They also reviewed recent advances in their newborn specialty.

Led by Joseph Danyo, MD, our first President, the organization expanded to a national venue in 1970 and evolved into the American Association for Hand Surgery. Dr. Danyo, along with Henry Burns, Carl Burner, Kim K. Lie, Julian Zweig, Walther Bohne, William Grabb, Lawrence Werschky, Leonard Glass, and Charles Kerschner contacted other alumni of Dr. Posch, who in turn recruited colleagues. Their effort culminated in an our Association, committed to Dr. Posch's precepts of excellence in patient care and continuing physician education and inclusive of all

physician that conducted hand surgery as a part of their practice.

There were sixty-five member physicians at the time of the Association's first meeting in 1971. Nearly 200 participants attended. Their enthusiasm was contagious. The meeting was a one day affair preceding the American Society of Plastic and Reconstructive Surgeons Annual Meeting.

The membership was expanded to include hand therapists, our partners in patient care and educational advancement. Over a thousand physicians and therapists belong to our organization today. The meeting has been expanded to 3 days. Our Annual Meeting is currently affiliated with those of the American Society of Reconstructive Microsurgery and the American Society of Peripheral Nerve. Attendance has markedly increased. Hand surgeons from all corners of the world attend and

some are International Members. The Association also supports seed grants for innovative research. The positive impact upon our most sacred mission of patient care has fulfilled the vision of Dr. Posch and our founders.

L. David Posch, Dr. Posch's grandson, along with our membership, has been inspired by his grandfather's quest for excellence. He has pursued the family vocation as a medical practice administrator and has wished to honor his grandfather's memory and legacy through a grant to initiate and sustain the Joseph L. Posch MD Award for the Best Resident and Fellow Presentation at the American Association for Hand Surgery Annual Meeting. Mr. Posch will present the first award on January 16, 2004, in Palm Springs, California. **H**

AAHS 2003 MEMBERS

Active Members

Bauer, John
Galveston, TX

Birdsong, Edward
Washington, NC

Brown, David
St Louis, MO

Burrows, James
West Valley City, UT

Chang, James
Stanford, CA

Cheng, Christine
St. Louis, MO

Gould, Lisa
Galveston, TX

Herron, Bryan
Prince Frederick, MD

Makhene, Ramotsumi
Flint, MI

Mohler, Randall
San Diego, CA

Morris, Stephen
Saginaw, MI

Mutz, Sterling
Orange, CA

Sanford, Steven
Charlotte, NC

Shah, Munir
The Woodlands, TX

Tanner, Cary
Fresno, CA

Tate, David
Sumter, SC

Affiliate Member

Page, Carol
New York, NY

Candidate Members

Ahmad, Nawaiz
Ridgeland, MS

Bernstein, Matthew
Hoffman Estates, IL

de Jesus, Ramon
San Francisco, CA

Rubin, J. Peter
Pittsburgh, PA

Westberg, Kirsten
Red Deer, AB, Canada

International Members

Houvet, Patrick
Paris, France

Kapila, Hari
Burwood, Australia

Woo, Sang-Hyun
Taegu, South Korea

Xiong, Ge
Beijing, China

President-Elect Susan Mackinnon, MD

Dr. Susan Mackinnon will assume the position of President-Elect of the American Association for Hand

Surgery at the Annual Meeting in January of 2004. She says that she has always found the AAHS to be an organization that not only excels in the continued education of hand surgeons, but importantly provides an environment that encourages friendly communication between its members. Susan is a native of Canada and graduated from the medical school at Queen's University in Kingston, Ontario, Canada. She trained in general surgery for three years at the same institution prior to completing her plastic surgery training at the University of Toronto. She completed a fellowship and studied peripheral nerve research at the University of Toronto in the Division of Neurosurgery and it was in this year that she began her research on nerve allotransplantation. In 1980 she was a hand fellow at the Raymond Curtis Hand Center in Baltimore. She then joined the surgical staff at the University of Toronto. Funded through the Medical Research Council of Canada, she did research investigating nerve regeneration through absorbable conduits studying the specificity of nerve regeneration and advancing this work to a clinical reality. In the 1980's in Toronto she continued her research work on nerve allotransplantation. Unlike solid organ transplants, the peripheral nerve allograft functions as a temporary structural scaffold or bridge across



which host axons regenerate to reinnervate distal host sensory and motor targets. She established that indefinite immunosuppression was not necessary. Dr. Mackinnon performed the first cadaver nerve transplant in 1988. In 1988 she was awarded the Medal Prize in Surgery from the Royal College of Physicians and Surgeons for her work on nerve regeneration.

In 1991 Susan moved to St. Louis with her husband, Dr. Alec Patterson, and four children to join the faculty in the Department of Surgery at Washington University School of Medicine. In 1996 she succeeded Dr. Paul Weeks as the Chief of the Division of Plastic Surgery. Her research work in St. Louis funded through the National Institute of Health continues to investigate nerve allotransplantation. Susan's research work has resulted in the use of peripheral nerve allografts clinically to reconstruct extensive and otherwise irreparable peripheral nerve injuries. Her current experimental focus is towards developing tolerance to the peripheral nerve allografts so that the potential side effects from systemic immunosuppression can be avoided. Dr. Mackinnon's surgical practice is restricted to problems related to nerve injury. Her laboratory work has allowed her to address numerous questions relating to nerve injuries and translate the laboratory findings to the management of her nerve injured patients. Her current clinical emphasis is on the use of innovative nerve transfers to reconstruct complex proximal nerve injuries by transferring an expendable source of nerve fibers close to the sensory/motor end targets. She is especially proud of the extremely productive residents and fellows

from many surgical specialties that have worked in her laboratory over the years.

Dr. Mackinnon is eager to continue to maintain the high standards set by previous association leaders. She looks forward to assuming a leadership role and continuing the precedent set by the American Association for Hand Surgery to advance education of hand surgery in a friendly inclusive and open environment. **H**

Candidates for AAHS 2004 Officers and Board



Officers

- President (automatic)
Richard Berger, MD, PhD
- President-Elect (automatic)
Susan Mackinnon, MD
- Vice President
Ronald Palmer, MD
- Treasurer (1 year left of 3-year term)
N. Bradly Meland, MD
- Treasurer-Elect
Richard Brown, MD
- Secretary
A. Lee Osterman, MD
- Historian
Jaiyoung Ryu, MD
- Parliamentarian
Scott Kozin, MD
- Senior Director At Large
Allen Bishop, MD
- Junior Director At Large
Mary Lynn Brown, MD
- Junior Affiliate Director
Aviva Wolff, MA, OTR, CHT

Elected Committee Positions

- Nominating Committee
Brian Adams, MD/Miguel Pirela-Cruz, MD

Scaphoid Fractures

The moderator for this *Around the Hand Table* is **Thomas R. Hunt, III, MD**, Head, Section of Hand Surgery, Department of Orthopaedic Surgery, The Cleveland Clinic Foundation, Cleveland, OH. Joining him in the discussion are hand surgeons **Joseph Imbriglia, MD**, Head of Hand Surgery and Professor of Orthopaedic Surgery, University of Pittsburgh, Pittsburgh, PA, **Alexander Y. Shin, MD**, Associate Professor, Mayo Clinic, Department of Orthopaedic Surgery, Division of Hand Surgery, Rochester, MN, and **Richard Uhl, MD**, Albany Medical Center, Albany, NY, and hand therapist **Carol Page, PT, CHT**, Hospital for Special Surgery, New York, NY.



I RESTRICT RADIAL AND ULNAR DEVIATION INITIALLY FEELING THAT THOSE MOTION STRESS THE FRACTURE THE GREATEST.

THOMAS R. HUNT, MD

Dr. Hunt: How are you handling patients that present with suspected scaphoid fractures based on mechanism of injury and physical examination with negative x-rays?

Dr. Shin: If you are referring to the occult scaphoid fracture, I think the traditional way of looking at this injury is with a bone scan. Otherwise a radiograph two weeks after injury can show signs of a fracture. We are actually using MRI more frequently because patients are starting to want an acute

diagnosis. And if they do have a fracture we're able to tell the patient what they're in for and a lot sooner than waiting two weeks.

Dr. Hunt: Dr. Uhl, how about you?

Dr. Uhl: While there may be some advantages to early diagnosis, I don't jump to the MRI. If a patient is tender in the snuffbox, and x-rays are negative, I will splint them for 10 to 14 days, and repeat the x-rays. If they are still quite tender, and the x-rays are still negative, I will usually get a CT scan. The CT will show if there is a fracture, and

if so, whether the fracture is displaced.

Dr. Hunt: Do either of you think CT or MRI necessitates a waiting period or are these tests an accurate means of diagnosing the fracture the day of the injury?

Dr. Uhl: MRI will show changes very early on, within six to twelve hours. The CT should show the fracture at any time.

Dr. Shin: MRI usually shows edema pretty early but is it really a fracture or is it a bruise within the scaphoid bone? We've had some patients that have had MRI's that have been positive but have never shown follow-up fracture on plain films or CT scans. The edema on MRI just disappears. I think you need to correlate the MRI with a follow-up plain film or CT scan to see if there's really a fracture. And it's usually about two to three weeks after their MRI is initially positive.

Dr. Hunt: Why do you choose MRI over CT, Dr. Shin?

Dr. Shin: The information obtained from a MRI is beneficial for both the surgeon and patient. Additionally, some non-displaced fracture initially will not show a fracture line or a pattern on a CT scan, whereas on MRI, you can see the edema and occasionally see the decreased signal intensity all across

the scaphoid that is consistent with a fracture. It also will rule out other injuries such as scapho-lunate ligament injuries or other soft tissue injuries.

Dr. Hunt: We tend to jump to an MRI sooner than in the past primarily because patients seem to demand an immediate explanation for their pain. They want focused treatment to begin as soon as possible in order to diminish time of immobilization. MRI allows me to give them an answer without a waiting period. I must admit, however, I have had a patient with a scaphoid fracture that was missed on the MRI and later diagnosed. When the MRI was re-examined the scaphoid fracture was clearly visible.

Dr. Shin: Prior to MRI's becoming popular, patients were immobilized and it would also take care of other concomitant injuries, or at least rest their "wrist sprain". But now with the socio-economic pressures today, patients want to know exactly what they have as soon as they possibly can.

Dr. Hunt: Let's say we diagnose a non-displaced or occult scaphoid fracture. What's the best way to treat that fracture?

Dr. Shin: Dr. Hunt, I think what you're alluding to is the treatment of an occult non-displaced waist fracture. There are a lot of treatment determinants and one of

them is concomitant injuries. What is the location and/or pattern of the fracture? And becoming more important are non-biologic factors, like time critical missions if you're in the military, or in professional sports. Socio-economic and financial impacts are important to consider. If you look at the acute screw fixation, whether percutaneous or open, a lot of people report that they can decrease the non-union rate. But I really think that's still yet to be determined. In a person that can tolerate cast immobilization, such as a high school student that's not involved in sports, then I would try cast immobilization. Whereas if it's an aggressive athlete trying to get back a scholarship, then I would offer percutaneous screw fixation. Bond et al in *JBJS* 2001 showed that patients were able unite their fractures at seven weeks with a screw versus twelve weeks in a cast. This also corresponded to an earlier return to work and activity.

Dr. Hunt: So you base your treatment, at least partially, on your belief that a non-displaced or minimally displaced scaphoid waist fracture will heal more quickly if surgically stabilized? But that you're not certain that fixing such a fracture reduces the non-union rate?

Dr. Shin: Right. In order to really figure out if surgery decreases non-union rate, you really have to have about 285 patients in an operative group and non-operative group to even detect a 5% non-union rate in the cast group and a 1% non-union rate in a screw group. And no such study has been done, and until one is done we don't know if it really does decrease non-union rates.

Dr. Uhl: I will usually treat a non-displaced or truly minimally displaced fracture in a cast. I remove the cast at six weeks and reexamine them. If they are not tender and the x-rays show healing, I will place them in a splint and obtain a CT scan. If the CT shows healing, I will leave them in the splint. If they are still tender, I will put them back in

a cast for two or three more weeks, and then get the CT scan. Now that being said, percutaneous screw fixation on the non-displaced fracture is a very expedient operation with minimum morbidity. This procedure has the advantage of getting the patient into a splint right away. I still would treat a high school student with a non-displaced fracture in a cast because there's a pretty good chance they're going to heal.

Dr. Hunt: How do you assess healing?

Dr. Uhl: I always check healing with a CT scan. We have all seen x-rays that look pretty good and get a CT scan and find that there is 30% union and 70% cleft. And that's probably not strong enough to return to unrestricted activities

Dr. Hunt: That brings us to treatment of casted, non-operated patients once they're out of the cast. Ms. Page, let's say you have a patient who's brought to you six to eight weeks after the initiation of casting. You are told that their scaphoid waist fracture is healing, maybe not completely, but they're non-tender and the doctor's pretty happy with the progression on x-ray. What do you do with them at that point?

Ms. Page: At that point we make them a custom molded thumb spica splint and start range of motion exercises, beginning with active and active assisted motion and gradually progressing. We hold off on strengthening until the fracture is well healed.

Dr. Hunt: Are there any particular motions you tend to withhold initially and add later or do you go with everything right off the bat?

Ms. Page: We usually start everything, wrist range of motion on all planes as well as pronation and supination. We start with active and active-assisted range of motion.

Dr. Hunt: Dr. Shin and Dr. Uhl, do you restrict any particular motions when you start your rehab program?

Dr. Shin: I typically do not because by the time I start the rehab program I try to be fairly certain that I have a good union and the fracture's on its way to healing.

Dr. Hunt: Dr. Uhl, do you feel the same?


Dr. Uhl: I agree. The motion that I would most be concerned with is the extension motion, which is usually the motion they are lacking. I would not deliberately push them into extension until I was quite sure the fracture was completely healed.

Dr. Hunt: I restrict radial and ulnar deviation initially, as I feel that those motions stress the fracture the greatest. I often use a scaphoid immobilization splint that allows flexion and extension but not radial or ulnar deviation. As motion improves and healing progresses, I add in those motions approximately three weeks later.

If you do choose to percutaneously stabilize a minimally displaced scaphoid waist fracture, what is your typical program in a patient returning to their high school football team as a linebacker? Dr. Shin?

Dr. Shin: For high school athletes, I try to hold them back from sports until I get some fracture union by CT scan and they're non-tender. But in the non-high school athlete or the working individual, after a percutaneous screw fixation I'll put them into an orthoplast splint and let them start gentle range of motion. I follow it with radiographs and interval CT scans. When it is starting to heal, I'll return them to light duty. Hopefully in four to six weeks they

continued on page 10



I THINK THAT A SCREW IS HELPFUL BUT ONLY IN A VERY SELECT GROUP OF PATIENTS SUCH AS ATHLETES...DENTISTS AND PROBABLY SURGEONS.

JOSEPH IMBRIGLIA, MD

Hand Surgery
Quarterly

.....

Winter
2004

AROUND THE TABLE

continued from page 9

can start normal duty after the fracture's healed.

Dr. Hunt: So you start your rehabilitation immediately?

Dr. Shin: About two weeks after the surgery. You have to get the soft tissue swelling diminished and let the other structures rest before you start range of motion.



I THINK A VERY PROXIMAL POLE FRACTURE IS ESSENTIALLY THE SAME AS A SCAPHOLUNATE LIGAMENT INJURY.

RICHARD UHL, MD

Dr. Hunt: What is the panel's preferred approach for screw fixation of a minimally displaced scaphoid waist fracture?

Dr. Uhl: I use a volar approach. If the fracture is fixed percutaneously, I make a small incision over the distal end of the tubercle and insert the guide wire retrograde into the proximal fragment. To fix a proximal fragment, I usually open dorsally and place the guide wire through the proximal frag-

ment into the body of the scaphoid in an antegrade direction.

Dr. Hunt: When you place your screw volarly, do you go through the trapezium or remove a small portion of the ridge off the trapezium?

Dr. Uhl: When fixing percutaneously, I go right through the tubercle. With a full volar approach, I often will take a little bite out of the trapezium to really get a better shot with the guide wire.

Dr. Shin: You know, I agree with Dr. Uhl. Whatever the surgeon chooses, it's important that they get that wire within the scaphoid for a min-

imally or non-displaced fracture. The screw has to be within the scaphoid and doesn't necessarily have to be right down the anatomic axis. However, in displaced fractures, you have to do a reduction, and place the screw down the anatomic axis.

Dr. Hunt: Dr. Imbriglia, how do you handle minimally or non-displaced scaphoid waist fractures, in general?

Dr. Imbriglia: In general, we treat them with non-operative treatment in a short arm thumb spica for six to eight weeks. In fact, I can't remember someone going on to a non-union with that treatment. The only time we're faced with doing something operative is in the athletes where they have to play this season.

Dr. Hunt: Have you had patients who you felt were clinically and radiographically healed following cast treatment and subsequently re-fractured when they returned to playing basketball or other sports?

Dr. Imbriglia: I get sent patients with that history and I actually think the bone never healed. They have another injury and the non-union then becomes symptomatic. I have seen where patients thought this was all healed, and a year later they come in and the bone never healed.

Dr. Uhl: I have not seen someone healed on a CAT scan, go out and re-fracture. I've seen where people thought they were healed on radiographs go out and re-fracture, and I think the situation is exactly what Dr. Imbriglia described.

Dr. Hunt: Do you think that a patient whose fracture was stabilized with a screw can return to activities earlier and with greater safety than a patient whose fracture was treated in a cast?

Dr. Imbriglia: I think the internal strut is helpful except for a very select group of patients, such as athletes who are either scholarship dependent or professional, and people

like dentists and probably surgeons, who literally cannot stay in a cast for eight weeks.

Dr. Shin: I think that extends to the person that's the only breadwinner for the family that needs to work to support a family.

Dr. Uhl: Dr. Imbriglia, do you let your athletes go back playing before the fracture is healed?

Dr. Imbriglia: We would not let a high school player play, but we would let a pro player.

Dr. Uhl: So do you wait for partial healing or do you let them go back right after surgery?

Dr. Imbriglia: We let them go back when their soft tissue swelling goes down, between three and four weeks after surgery. They can wear a very well-padded brace.

Dr. Hunt: That's how I manage our athletes here as well, but certainly it's sport- and position-dependent as far as when they can return to play.

Dr. Hunt: Let's talk a little bit about non-unions. We've just mentioned that we don't feel that screw fixation necessarily lessens the non-union rate. What do you all feel is the natural history of a scaphoid non-union?

Dr. Uhl: Based on the literature, the natural history is they go on to arthritis. But, I've seen several variations. Some have a stable fibrous union and seem to do well; some go on to a limited styloid arthritis; and many go on to the full blown arthritis. I don't know that it's quite the 98% that is quoted in the literature.

Dr. Imbriglia: I think the natural history is arthritis occurring between the radial styloid and the distal pole of the scaphoid. You see that x-ray picture much more than total destruction of the wrist. That's why you can, strangely enough, save the wrist that has the scaphoid non-union more often than you can save the wrist that

has the scapho-lunate dissociation, where much more of the scaphoid is arthritic. It always amazes me how the proximal pole is preserved in scaphoid non-union, whereas in scapho-lunate dissociation, the proximal pole is the first to go. Eventually the whole wrist goes.

I'm sure we've all seen people in their 70's with terrible looking wrists who said they broke their wrist in college. They broke their scaphoid and it took about forty or fifty years for it to wear out. So you can catch these people early, and that's why styloidectomy and resection of the distal pole are very reasonable procedures in a lot of people. You can save a lot of wrists with simple procedures.

Dr. Hunt: Dr. Shin, what do you think?

Dr. Shin: There's such a wide variability of patients that it's difficult to give them one treatment and see and compare it to another. There are factors such as age, the duration of their non-union, whether they are in a DISI stance, in neutral carpal alignment, or have mid-carpal arthritis. Additionally, there are so many different treatment options. We've even had patients that want very little done, and just doing neurectomies and taking out that pain in the radial aspect of the wrist with a selective neurectomy has given them five, six years of good relief before they go onto another type of treatment.

Dr. Hunt: How about the proximal pole non-union that's non-displaced? What do you think will happen with those and what is your preferred approach to treatment?

Dr. Shin: Well, I think it really depends on the location. I think some authors, like Steve Viegas, have shown the different configurations for that proximal pole non-union. Some are quite stable and some are quite un-stable. The stable ones might do well with just observation. Otherwise, my treatment of choice is vascularized bone grafts because of the size and location.

Dr. Hunt: That brings up a question. How do you evaluate a patient pre-operatively with the scaphoid non-union?

Dr. Shin: I like to get plain radiographs, and CT scans to determine the bony architecture and then a gadolinium-enhanced MRI to assess vascularity of that proximal pole fragments.

Dr. Hunt: Dr. Imbriglia, do you use gadolinium-enhanced MRI's to help assess vascularity for all patients?

Dr. Imbriglia: I use it for some; I don't use it for all patients. Obviously, the more proximal the fracture, the more I'm worried, particularly if there's any displacement. I would use it with proximal pole fractures. For some of these, if they're avascular, then the operations to internally fix them may be doomed to failure, and some other procedure should be considered.

Dr. Hunt: Which other procedures?

Dr. Imbriglia: Depending on the size of the fragment, I will excise the fragment and do a capsulodesis between the lunate and the scaphoid. In other words, if you have a fragment less than a fifth or a sixth of the entire scaphoid and you have proven ahead of time it's avascular—and it looks avascular when you open it up—I will excise it and do a capsulodesis. The recovery is very fast. The argument against excision is that they will go onto scapho-lunate dissociation. I don't think that happens as frequently as you might think. You can save some wrists by doing that, as opposed to too much surgery where you try to do the impossible.

Dr. Hunt: Are you for or against vascularized bone grafts?

Dr. Imbriglia: I have done vascularized grafts in certain situations in proximal pole fractures. I think it's like all techniques; it can be overused if the fragment is small enough and avascular. You can force a patient to have a couple of operations instead of just one. You

can't make every proximal pole fracture heal if they're small and displaced. In those cases, I will excise it.

Dr. Uhl: So you're looking to avoid staged wrist surgery, so to speak.

Dr. Imbriglia: Right. And you've seen that a lot.

Dr. Uhl: Sure.

Dr. Imbriglia: Many patients have big operations, long periods of immobilization and end up with a stiff wrist. You can't tell from the literature the right thing to do. But your experience can tell you at a certain point that you don't want to do something that only has a 50% success rate.

Dr. Hunt: Dr. Shin, how have your patients done with vascularized bone grafts in terms of functional restoration?

Dr. Shin: That's a great question because, in fact, I'm in the process of looking at our last probably ten years' worth of vascularized bone grafts because of the article that came out by Tim Davis in the *British Journal*, which showed a 73% failure rate of vascularized bone grafts in 22 established scaphoid non-unions. Early analysis of our data shows we have some failures, but not as great as the group in Nottingham. The indications for vascular bone grafts have to be realistic. I agree with Dr. Imbriglia that that really tiny fleck of proximal pole with not enough surfaces for a screw really is not the indication. Perhaps a salvage procedure or capsulodesis might be better. But you have to really look at these carefully to see if the vascularized

continued on page 12



IF THE PROXIMAL POLE IS AVASCULAR, AND THERE IS A HUMPBACK DEFORMITY, I PREFER A VOLAR ILIAC CREST WEDGE GRAFT AND AN AV PEDICLE FROM THE DORSAL INTERCARPAL ARCH TO REVASCULARIZE THE PROXIMAL POLE.

ALEXANDER SHIN, MD

Hand Surgery
Quarterly

.....
Winter
2004

11

AROUND THE TABLE

continued from page 11

bone graft actually will work. It's a technically difficult operation and you have to be really gentle with the pedicle. I've seen people take a tap and just bang on that pedicle and you can't expect the bone graft to survive with that kind of treatment.



AFTER A VASCULARIZED GRAFT, THERE IS A LONGER DELAY BEFORE THEY START THERAPY AND WE NEED TO PROTECT THE GRAFT.

CAROL PAGE, PT, CHT

Dr. Hunt: Ms. Page, have you seen much difference in trying to rehab somebody from vascularized bone graft post operative-ly? Are they stiffer?

Ms. Page: I think we have to go much more slowly. Sometimes, we've put them into a sugar tong or muenster splint rather than a thumb spica splint when they are referred to us to start therapy. Obviously, there is usually a much longer delay before they can start therapy, and we need to take it more slowly, so they do tend to be stiffer for the reasons that others of you have brought up. The

combination of the surgery with a long period of immobilization causes stiffness, but we can't be aggressive to regain range of motion because we want to protect the bone graft.

Dr. Hunt: Dr. Shin, how do you manage the patient who may have an avascular proximal fragment based on a gadolinium-enhanced MRI, combined with a humpback deformity?

Dr. Shin: In the patient that has a humpback deformity, the use of a vascularized bone graft, for example, from the dorsal radial aspect of the radius, is very difficult.

Harvesting a big enough piece of bone to restore the normal architecture and normal angles of the scaphoid is challenging. In this case, I prefer to do a volar approach, using iliac crest bone graft, as described by Diego Fernandez. If the proximal pole is avascular, and there is a humpback deformity, I prefer a volar iliac crest wedge graft and an AV pedicle from the dorsal intercarpal arch to revascularize the proximal pole.

Dr. Uhl: So, you have two incisions, polar and dorsal.

Dr. Shin: That is correct. Alternatively, you could use the superficial branch of the radial artery, but typically it is too short.

Dr. Hunt: Any other comments on that particular clinical problem?

Dr. Imbriglia: Well, if it's a waist fracture, most of the time you do the volar approach and wedge it up and put in the bone graft. I have not added a vascularized pedicle to that. I guess if it was more proximal than the waist, but I actually think most of the time that the waist fracture, even if it is displaced and humpbacked, can be propped up with a free bone graft. And I must say, I just use the radius. I don't use the iliac crest anymore. Despite some of the papers that said the iliac crest is necessary, I never understood that: I just used the radius. So, it's one incision volarly at the radius, and I do use a screw in that case. And, I have felt pretty comfortable with that. Obviously as the fracture gets more proximal, I think that's where you have to consider the vascularized graft. But mid-waist, even if you thought, well it looks a little vascular, most of the time you can do the routine procedure.

Dr. Uhl: So, even if you have an MRI which seems to imply that it's avascular, you pretty much use a standard treatment for that?

Dr. Imbriglia: Yes, I do, and I do what is in David Green's article, I try to make a drill hole in it and see if I

see any bleeding. Most of the time it's not chalky. You know, when these are bad—when they're real proximal—they're like chalk. And those are the ones I give up on and take out. Mid-waist usually is not like that. Even if the MRI says it's somewhat avascular, I think most of the time you can salvage those.

Dr. Shin: I have to agree with Dr. Imbriglia. Occasionally, the gadolinium-enhanced MRI says it's completely avascular and punctate bleeding is visible. In the cases where it's completely avascular and just a shell of bone, if you pack it with some bone graft, then you might need the AV bundle put in there too.

Dr. Imbriglia: Right.

Dr. Hunt: We touched briefly on the subject of avascular proximal pole scaphoid non-unions. Dr. Imbriglia, you mentioned excision and capsulodesis. Does anyone else have any other way of approaching this difficult clinical problem?

Dr. Uhl: A very proximal pole fracture is essentially the same as a scapho-lunate ligament injury. The real problem is the incompetence of the scapho-lunate joint and the subsequent deformity. I think to approach it like a scapho-lunate ligament tear, which is what Dr. Imbriglia said, is the right way to think of it.

Dr. Hunt: Does anybody use multiple K-wires?

Dr. Shin: I try to use a screw if possible to place dorsally, and I usually use a vascularized bone graft accompaniment with that. Or, if you can't do that, usually two, maybe three, K-wires, placed dorsally. You tap it right against the articular cartilage and leave them just under the skin volarly so they can be removed at a later time.

Dr. Imbriglia: You're referring to these very small proximal poles, right?

Dr. Hunt: I was referring to those proximal pole fractures that are too small for even a mini-screw.

continued from page 14

a big fan of proximal row carpectomy. Is there any role for that operation for this injury?

Dr. Imbriglia: The answer is no. I would certainly not make that my first choice. Either with the fusion or proximal row, what you're really saying to the patient is, we're going to limit both your motion to some degree and your strength to some degree, for the rest of your life. And you must do that in certain situations where, as you said, there's mid-carpal collapse or severe enough arthritis at the radial-scaphoid junction. Most of these patients don't have that though. Most of these patients are there earlier than that. And that's why I would try something less than that—denervation, excision of the proximal pole, capsulodesis—to try to preserve both rows of the carpus and a more normal wrist. And even if you get ten years out of it, which I think you often will, or even longer, then that's worth it for the patient.

Dr. Shin: Has anyone tried removal of proximal pole and scapho-capitate arthrodesis?

Dr. Imbriglia: I have not. I just do a capsulodesis and I can say, anecdotally, that I haven't had to go back. I've always been kind of against it, and only when pushed do I do intercarpal arthrodesis.

Dr. Hunt: Dr. Shin, that's probably what I would do if I was in that situation and felt that if I excised that proximal pole fragment, it would immediately collapse.

Dr. Imbriglia: Well, the interesting thing to me is that through all this discussion about an unstable scaphoid, no one has mentioned triscaffa fusion. I really believe that has gone by the wayside.

Dr. Uhl: I was going to say, does anyone still do that operation?

2005 Application for Research Grants

The AAHS Research Grant Awards were established to further the purpose of the Association as stated in its Bylaws and to foster creativity and innovation in basic and/or clinical research in all areas pertinent to hand surgery.

Awards and Eligibility

Grants will be made for a one year period to up to three investigators. Grants are available to all AAHS members. One of the investigators must be an active or affiliate member of the association.

Grant Application

Applications may be obtained from the AAHS website at www.handsurgery.org, or, you can call 312-236-3307 to request a copy.

Applications (an original plus seven copies) must be received by the committee chair no later than Monday, November 1, 2004, in order for the judging to be completed in time and the recipients to be announced at the Annual Meeting.

The AAHS and the Research Committee are required by the IRS to document disbursement of grant funds. Award recipients will be required to sign a letter of acceptance and submit a progress report once each year. The AAHS must be acknowledged as the source of funding in any presentation or publication. A final report must be submitted at the completion of the study. It is expected that the results of the funded research be submitted for presentation at an Annual Meeting within two years of the receipt of the award. Funds must be returned to the AAHS if the study is not undertaken within twelve months of the receipt of the award.

Failure to follow these guidelines will disqualify the recipient from any further grant opportunities and from presenting any papers at the AAHS Annual Meeting for a period of three years following such default.

Mail Grant Proposals to

W. P. Andrew Lee, MD
University of Pittsburgh
3550 Terrace Street
Scaife Hall 690
Pittsburgh, PA 15261



Dr. Imbriglia: I can say I never did and I'm glad it's gone.

Dr. Shin: I would have to second that.

Dr. Imbriglia: It was overrated and one of those things in the literature that changed things for the worse.

Dr. Hunt: Are there any other questions that the panel would like to discuss?

Dr. Imbriglia: Yes, actually there's one other interesting thing. What do all of you think about doing a radial styloidectomy and excising the distal pole in a SLAC wrist, or SLAC wrist grade one, where the arthritis is limited to those areas?

Dr. Uhl: I have done several styloidectomies and I don't excise the distal pole, but I take off the big osteophyte. They have really done pretty well.

Dr. Shin: I have seen patients that have undergone distal pole excision

for scaphoid non-unions and they have done remarkably well. I am a believer in the procedure that Malorich and Eaton described and I think it's a very good procedure to be done in a very specific patient population.

Dr. Hunt: Exactly which patient population, Dr. Shin?

Dr. Shin: I think in the young worker with a painful scaphoid non-union with no evidence of carpal collapse that does not want an intercarpal fusion and wants to return to work quickly.

Dr. Imbriglia: Well that's been our experience. We think this has been a wonderful salvage procedure that has minimal morbidity, you don't lose anything, and the patient is moving their wrist within ten days.

Dr. Shin: It's incredible.

Dr. Imbriglia: We think it's a great addition to what we do.

Dr. Uhl: Dr. Imbriglia, how completely do you remove the distal pole of the scaphoid? Or do you leave part of the articulation on the ulnar side still in or do you make sure you get all the way over to the capitate and get every piece?

Dr. Imbriglia: Oh no, we take it all out. I actually don't think it would probably matter, but we just go in where the non-union occurs and take the pole out.

Dr. Uhl: And you go volar or dorsal?

Dr. Imbriglia: We would do that, in general, from a sort of dorsal-radial approach.

Dr. Hunt: Does the size of the distal fragment make a difference? What if it's a fracture at the junction of the mid and proximal thirds?

continued on page 16



Help us collect 100,000 stethoscopes for doctors around the world who need them.

Ways to donate a stethoscope:

Order a stethoscope through AMA PracticeLink.

Purchase a stethoscope from a vendor of your choice.

Organize a stethoscope collection at your hospital, medical school, office practice, or local medical society.

For more information:

Web www.caring4humanity.org

Phone 888 881-6744

Email caring@ama-assn.org

American Medical Association

Physicians dedicated to the health of America



AMA Foundation

Hand Surgery
Quarterly

.....
Winter
2004

15

AROUND THE TABLE

continued from page 15

Dr. Imbriglia: We would still do it. I have pushed it. The x-ray can look scary, but the truth is, for some reason, even if it's like, a third of the scaphoid, it's just enough to support the capitate. I'm sure you've all seen you can't take the whole scaphoid out because then, in general, the capitate will fall down. But I've pushed it to about a third of the proximal pole and haven't seen a complete collapse yet. But I'll let you know if it occurs.

Dr. Uhl: And does the lunate tend to tip dorsally?


Dr. Imbriglia: I think most of these people already have a little bit of dorsal instability pattern and I haven't seen it get worse.

Dr. Hunt: Any other thoughts? Dr. Shin, do you believe in it?

Dr. Shin: I'm a believer.

Dr. Hunt: Do you have a feel for the long-term results of that procedure?

Dr. Imbriglia: For the long-term outlook, and this is again philosophical, if they are doing well at six months, I'll bet they're doing well at ten years because there's nothing to wear out. There's no reason for things to wear out because their pain is localized. You've seen that, their swelling and pain is localized to the radial side and as long as they don't collapse, you're okay; I haven't seen them collapse any further. Most of the time, you take that distal pole out but the scapho-lunate ligament is still intact and you have just enough scaphoid to help support the capitate.

Dr. Hunt: Very good. That concludes our discussion for now. Thank you all very much. 

Hand Surgery
Quarterly

.....

Winter
2004

16



AMERICAN ASSOCIATION FOR HAND SURGERY

Annual Meeting Dates

| |
|------------------------------|
| JANUARY 8-11, 2003 |
| Hyatt Regency Kauai |
| Kaunoi, Kauai, Hawaii |
| JANUARY 16-17, 2004 |
| Westin Mission Hills |
| Palm Springs, California |
| JANUARY 12-15, 2005 |
| Sanibel Harbor Resort |
| Sanibel Island, Florida |
| JANUARY 11-14, 2006 |
| Loews Wildfire Canyon Resort |
| Tucson, Arizona |

Call 312-236-3307
FOR MEMBERSHIP INFORMATION

PHYSICIAN, RESIDENT, THERAPIST WELCOME

AMERICAN ASSOCIATION
FOR HAND SURGERY

HAND PATIENT EDUCATION BOOKMARKS



Available For Purchase

Bookmarks are available in quantities of

50 FOR \$25

You may fax your order directly to
312.782.0553, or mail to AAHS,
20 N. Michigan Ave., Suite 700,
Chicago, IL 60602.

Name: _____

Address: _____

City: _____ State: _____ Zip: _____

Phone: _____

Check Enclosed

(Please make check payable to AAHS Central Office, 20 N. Michigan Avenue, Suite 700, Chicago, IL 60602)

Visa

Master Card

American Express

Card Number: _____ Expiration Date: _____

Name As It Appears On Card (Please Print) _____

Signature: _____

TOTAL AMOUNT ENCLOSED \$ _____

(Please add \$3.00 for shipping and handling)

Scaphoid Fractures

This issue of the Coding Corner deals with scaphoid fractures. Codes for these fractures can be grouped into acute and non-acute clinical scenarios.

There are five main codes that deal with surgery for acute scaphoid fractures. Code 25622 refers to closed treatment of the fracture without manipulation, whereas 25624 is used for closed treatment with manipulation. Perhaps the most common procedure, open surgical treatment (with or without internal fixation) is coded with 25628. Note that if autogenous bone is used, additional bone graft codes can be added (20900 or 20902, depending upon how much graft is needed). Treatment of an acute scaphoid fracture as part of managing a

trans-scaphoid peri-lunate dislocation is coded with 25680 if management is closed; open treatment is coded with 25685.

Scaphoid nonunion care is categorized under "reconstruction" rather than "fracture" codes. Surgery to repair a nonunion is coded with 25440. Note that this code includes both obtaining bone graft, using internal fixation, and performing a radial styloidectomy. A procedure for which there is no specific code as yet is use of a vascularized bone graft to treat a scaphoid nonunion. This can, however, be coded with a combination of existing codes. First, the fracture code for open treatment, 25628, can be used. Next, code 25430 can be added, since this describes insertion of a vascularized pedicle into a carpal bone. Lastly, the use of autogenous bone graft would be added with code 20902. If vascularized

| Scaphoid Fractures | |
|--------------------|---|
| Acute Injury | |
| 25622 | Closed treatment of scaphoid fracture, without manipulation |
| 25624 | Closed treatment of scaphoid fracture, with manipulation |
| 25628 | Open treatment of scaphoid fracture, with or without internal or external fixation |
| 25680 | Closed treatment of trans-scaphoid peri-lunate fracture dislocation |
| 25685 | Open treatment of trans-scaphoid peri-lunate dislocation |
| Reconstruction | |
| 25440 | Repair of nonunion, scaphoid, with or without radial styloidectomy (includes obtaining bone graft and necessary fixation) |
| 25430 | Insertion of vascular pedicle into carpal bone |
| 20900 | Bone graft, any donor area, minor or small |
| 20902 | Bone graft, any donor area, major or large |

bone graft procedure is being performed for a well established nonunion, the nonunion reconstruction code can be used (25440) with the vascularized pedicle code (25430); an additional bone graft code is not required since 25440 includes obtaining bone graft.



LEON S. BENSON, MD

The various procedures and corresponding codes for treating scaphoid fractures are summarized in the table above.

You Code It

A 21-year-old college student presents with chronic wrist pain from an injury that happened "a while ago." Work-up reveals a well established scaphoid nonunion without associated arthritic change in the wrist. Due to the proximal location of the nonunion and diminished blood flow shown on MRI, a vascularized bone graft procedure is selected for treatment.

Solution:

25440. Repair of nonunion, scaphoid, with or without radial styloidectomy (includes obtaining graft and necessary fixation)
25430. Insertion of vascular pedicle into carpal bone. **ii**

"East Meets West"

Post-IFSSH Congress
 June 19-21, 2004

Bucharest, Romania
 following the IFSSH meeting in
 Budapest, Hungary



This meeting is organized by the **Romanian Society for Surgery of the Hand** and the **American Association for Hand Surgery**, and is endorsed by the RSRM, ASRM and IFSSH. The post-congress will be held in an area of Europe well known for its natural beauty, history, art, and architecture and will offer an academic program of benefit to both hand surgeons and microsurgeons. Please contact the AAHS representative for the congress, Jaiyoung Ryu at jryu@adelphia.net for further information, or visit the website at: <http://www.postifssh2004.ro/>

Online Medical News and Information: The Eye of the Needle in the Haystack



CHARLES EATON, MD

I love to search for information—it's the way I was raised. My father answered most factual questions or arguments in the family with the call, "Let's look it up!"—the signal for us to all circle around the dictionary or encyclopedia. That's fun, doing a swat mission on an orga-

nized resource. What's not as fun is trying to find an info-bite in a disorganized mess, like my office, or worse yet, the internet. But I still love to search, and the internet is a one stop shopping area for information. Here are some of the strategies that I currently use to make the most out of what's available online for free.

Browsing a specific hand topic

You might, for example, need to research nondisplaced scaphoid fractures. Where to look?

Medline

The motherload, always improving, is Medline. The National Library of Medicine's Medline search engine is called PubMed, at www.ncbi.nlm.nih.gov/entrez/query.fcgi?db=PubMed. Bring up that page in your browser, enter "nondisplaced scaphoid" and you'll see a list of citations



Figure 4

(Figure 1). You can click on each to read the abstracts one at a time, but it's faster to use the "abstract" view (Figure 2). Choose this from the drop down menu next to the "display" button, and you can browse abstracts all on one page (Figure 3). PubMed defaults to 20 citations per page, but you can put more on display so that you don't have to keep clicking on "next page" for more. To do this, choose up to 500 to be displayed at a time (Figure 4) and then click on the "display" button again. Finally, if you want to review your search in your favorite word processor rather than your web browser, choose "file" in the menu next to the "Send to" button (Figure 5), and then click on the "Send to" button. This will prompt you to save a file called "query.fcgi" —but it's probably better at that point to enter something like "scaphoid.txt" as the name for the saved file so that your computer will know that it's a text file. This little step gives you much more freedom to play with the

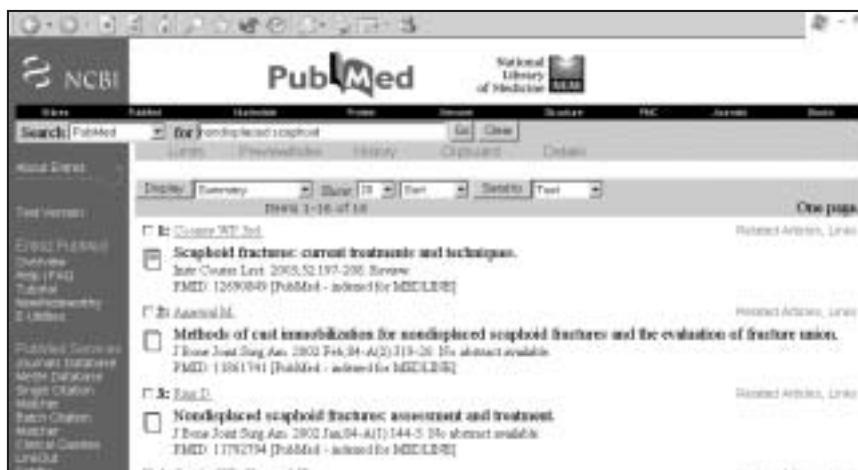

Figure 1

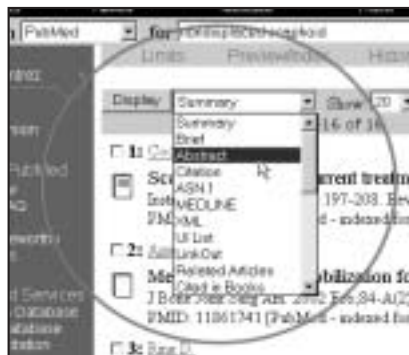

Figure 2




Figure 3




Figure 5

search results—and it saves the entire search output, not just the ones displayed on your current browser page.

Google

OK, Medline is a bit too stuffy—what about the people’s search engine? Lucky for you, Google, www.google.com, recently added PubMed to its database. Go to Google, enter “nondisplaced scaphoid” (without the quotes), and you’ll get a wider selection, including both PubMed results and online articles not referenced by PubMed. It’s a bit more cluttered, and will include links to lists of personal publications, scientific session program headings and other title-only links, but is a helpful additional resource. Two search syntax tips are helpful to narrow your Google searches. First, use quotes around exact phrases (e.g. “nondisplaced scaphoid”) to weed out links to pages that have both “nondisplaced” and “scaphoid” but not the actual phrase. Second, add “index of” (with the quotes) to your search if you are looking more for a directory of files—especially helpful if browsing for images.

Amazon

What if you want to find a reference that’s in a book, not a journal? What if the title of the book doesn’t have “nondisplaced scaphoid” in its title or chapter headings? Again, lucky for you, Amazon, www.amazon.com, has just upped the ante with a full text “Search inside the book” feature. This option is a bit controversial, and may face copyright challenges, but for now, it’s available. Go to Amazon, (you have to sign in as a member, but it’s free), select

“books”, enter “nondisplaced scaphoid” (without the quotes), and boom!—a list of books with these words in the text, along with a little text clip showing the words in the actual relevant text from the book. This is a huge step forward in online searching.

e-Hand

What if you’re lazy? Again, you’re in luck. e-Hand, www.e-Hand.com, has a search tool which will let you enter a search phrase, and then let you choose the search engine (Figure 6). This is available at www.e-Hand.com/frame.htm?new&stuff, and includes a variety of different databases’ engines, including the ones mentioned above.

What’s new?

Want to keep up to date on breaking reports in hand surgery? Several search engines can be configured to sort their output by date, starting with the most recent files. Preconfigured “most recent” hand surgery searches, including PubMed, DocGuide and Google

News are also available at www.e-Hand.com/frame.htm?new&stuff. Want to be able to impress your colleagues with your knowledge about non-hand breaking medical news? Check out Medline plus news at www.nlm.nih.gov/medlineplus/newsbydate.html. This

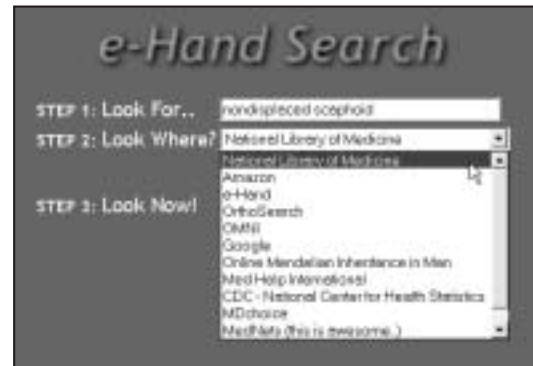

Figure 6

list, updated daily, links to all top medical stories in the news from a large number of sites—very interesting casual reading, always current, highly recommended.

Have fun and happy searching!



| AAHS 2004 SLATE OF MEMBERSHIP APPLICANTS | | |
|---|---|---|
| Active Members | Affiliate Member | McAdams, Timothy <i>Palo Alto, CA</i> |
| Budoff, Jeffrey <i>Houston, TX</i> | Blake, Christine <i>Mt. Pleasant, SC</i> | Nasser-Sharif, Susan <i>Wilmington, DE</i> |
| Kalliainen, Loree <i>Columbus, OH</i> | Candidate Members | Spinner, Robert <i>Rochester, MN</i> |
| Ladd, Amy <i>Palo Alto, CA</i> | Avena, Ricardo <i>Louisville, KY</i> | Wolf, Jennifer <i>Rochester, MN</i> |
| Malerich, Matthew <i>Bakersfield, CA</i> | Beck, Joel <i>San Mateo, CA</i> | |
| Matiko, James <i>San Bernardino, CA</i> | Bueno, Reuben <i>New York, NY</i> | |
| Stafford, James <i>Houston, TX</i> | Lionelli, Gerald <i>St. Peters, MO</i> | |

American Association for Hand Surgery Calendar

2004

January 14-17, 2004
34th Annual Meeting
Westin Mission Hills
Palm Springs, CA

March 10-14, 2004
American Academy of Orthopaedic
Surgeons Annual Meeting
San Francisco, CA

May 21-23, 2004
Work Related Disorders of the
Upper Extremity
Wyndham Chicago
Chicago, IL

July 9-11, 2004
Mid-Year Board of Directors'
Meeting
St. Regis Monarch Beach Resort
Dana Point, CA

September 9-11, 2004
American Society for Surgery of the
Hand – 59th Annual Meeting
New York, NY

2005

January 12-15, 2005
35th Annual Meeting
Sanibel Harbor Resort
Sanibel Island, FL

July 15-17, 2005
Mid-Year Board of Directors'
Meeting
The Lodge & Spa at Cordillera
Edwards, CO

September 22-24, 2005
American Society for Surgery of
the Hand – 60th Annual Meeting
San Antonio, TX

2006

January 11-14, 2006
36th Annual Meeting
Loews Ventana Canyon Resort
Tucson, AZ

July 14-16, 2006
Mid-Year Board of Directors'
Meeting
The Broadmoor Hotel
Colorado Springs, CO

September 7-9, 2006

American Society for Surgery of
the Hand – 61st Annual Meeting
Washington, DC

2007

January 10-13, 2007
37th Annual Meeting
The Westin Rio Mar
Beach Resort
Rio Grande, Puerto Rico

2008

January 9-12, 2008
38th Annual Meeting
The Westin Century Plaza
Hotel & Spa
Beverly Hills, CA

For information contact:
AAHS Central Office at
312-236-3307 or
www.handsurgery.org

HAND SURGERY
QUARTERLY



www.handsurgery.org
20 North Michigan, Suite 700
Chicago, IL 60602

PRSR STD
U.S. Postage
PAID
Documation

Inside This Issue:

- 1 2004 Annual Meeting Preview
- 3 From the President
- 4 2004 Program at a Glance
- 6 Leadership Profiles: The Joseph L. Posch, MD Award and President-Elect Susan Mackinnon, MD
- 8 Around the Hand Table: Scaphoid Fractures
- 17 Coding Corner
- 18 The Digital Hand Surgeon